



## PATIENT

Bruna Baena

## SPECIES

Canine

## BREED

Mix

## SEX

FS

## AGE

9

## WEIGHT

43.2

## INTERPRETED BY

R. McKenzie Daniel,  
DVM, DABVP  
(Canine and Feline)

## IMAGING PERFORMED BY

Jenn

## HOSPITAL NAME

Rockaway Animal  
Hospital

## REFERRING VET

Dr Maniar

## INVOICE 24287

**DATE**  
03/25/2026

## PRESENTING CLINICAL SIGNS

diarrhea

Abnormal PE/Chem/CBC/UA Results: ALB 4.3 ALP 297 Lipase 281

## ULTRASONOGRAPHIC EXAMINATION OF THE ABDOMEN

### Urinary System

The urinary bladder, trigone, cystourethral junction, and visible pelvic urethra exhibited normal thickness and tone. Anechoic urine was present in the lumen with no evidence of urine/lumen sediment, mineral, or calculi. The ureteral papillae were normal. The ureters were not visible which is normal. No evidence of inflammatory or neoplastic changes was noted.

Normal size and margination were present in the kidneys. A normal 1:3 cortex / medulla ratio and normal corticomedullary definition were maintained. The echogenicity of the cortex was similar to or slightly less than normal liver parenchyma while the medulla echogenicity was hypoechoic to the cortex with no evidence of pelvic dilation. The left kidney measured 5.9 cm in length. The right kidney measured 5.7 cm in length.

The area of the aortic trifurcation was free of pathology.

### Adrenal Glands

The left adrenal gland was uniform in size and contour with a uniformly hypoechoic parenchyma. The left adrenal gland measured 0.59 cm width at the caudal pole. The right adrenal gland was uniform in size and contour with a uniformly hypoechoic parenchyma. The right adrenal gland measured 0.68 cm width at the caudal pole.

### Spleen

The spleen exhibited a finely textured and homogenous parenchyma which was hyperechoic to the liver and renal cortical parenchyma. The capsule was smooth and regular without apparent expansion. The splenic vasculature at the hilus was normal in volume with no evidence of congestion or thrombosis. Acute to chronic inflammatory, neoplastic, or benign parenchyma changes were not noted.

### Liver/Gallbladder

The liver was subjectively normal in size, structure, and contour. The liver parenchyma was uniform and hypoechoic to the spleen with a mild coarse echotexture. Normal vascular volume. The hepatic and portal vasculature were normal in appearance without signs of congestion. The gallbladder was non-distended in size with thin walls and primarily anechoic luminal content. The cystic and common bile ducts were normal.

### Gastrointestinal

The stomach presented intact wall layering with a normal wall layer ratio. The lumen of the stomach contained mild variably echogenic non-shadowing ingesta with no signs of obstruction or foreign material.

The small intestine presented intact wall layering with 1:3 muscularis/mucosa ratio. The lumen of the small intestine was empty with no signs of mechanical/metabolic ileus, obstruction or foreign material.



## PATIENT

Normal visible colon wall layers were present with semi formed to possible soft feces in lumen.

Bruna Baena

## *Pancreas*

The parenchyma of the left limb, body and right limb of the pancreas presented isoechoic to the adjacent omental fat. A normal curvilinear capsule contour of the pancreas was present. The visible pancreatic duct was normal. No signs of active inflammation or neoplastic disease was evident.

## SPECIES

Canine

## *Free Abdomen*

## BREED

No omental masses, overt lymphadenopathy or peritoneal effusion was present.

Mix

## ULTRASONOGRAPHIC FINDINGS

### Primary

## SEX

- Sonographically normal gastrointestinal tract/colon with non-shadowing gastric ingesta and semi-formed to soft fecal matter in colon
- Normal area of pancreas
- Sonographically normal liver - consistent with mild benign hepatopathy

FS

## AGE

9

## INTERPRETATION OF THE FINDINGS & FURTHER RECOMMENDATIONS

The appearance of the gastrointestinal tract is non-specific with considerations including dietary intolerance / food hypersensitivity, infectious disease, dysbiosis, enterotoxin, inflammatory bowel disease, mild pancreatitis, occult parasitism, occult Addison's Disease, or other.

## WEIGHT

43.2

A GI panel to include PLI/TLI/Cobalamin/Folate, fresh fecal analysis to assess for parasitic ova / Giardia and resting cortisol is warranted.

## INTERPRETED BY

R. McKenzie Daniel,  
DVM, DABVP  
(Canine and Feline)

Empirically, a limited antigen or hydrolyzed diet trial with potential long term dietary therapy, prophylactic deworming (Panacur 50 mg/kg SID x 5 consecutive days with repeat protocol in 3 weeks even if fecal testing is negative), high colony count probiotic (Provable or Visbiome), cobalamin supplementation pending assessment of cobalamin level +/- antibiotic trial with consideration for adverse effects on normal GI flora with long term antibiotic use and as needed gastrointestinal support with assessment of clinical response may prove beneficial. Intestinal biopsies may be indicated if GI signs continue despite empirical therapy.

## IMAGING PERFORMED BY

Jenn

## HOSPITAL NAME

Rockaway Animal  
Hospital

## REFERRING VET

Dr Maniar

## INVOICE

24287

## DATE

03/25/2026



**PATIENT**

Bruna Baena

**SPECIES**

Canine

**BREED**

Mix

**SEX**

FS

**AGE**

9

**WEIGHT**

43.2

**INTERPRETED BY**

R. McKenzie Daniel,  
DVM, DABVP  
(Canine and Feline)

**IMAGING PERFORMED BY**

Jenn

**HOSPITAL NAME**

Rockaway Animal  
Hospital

**REFERRING VET**

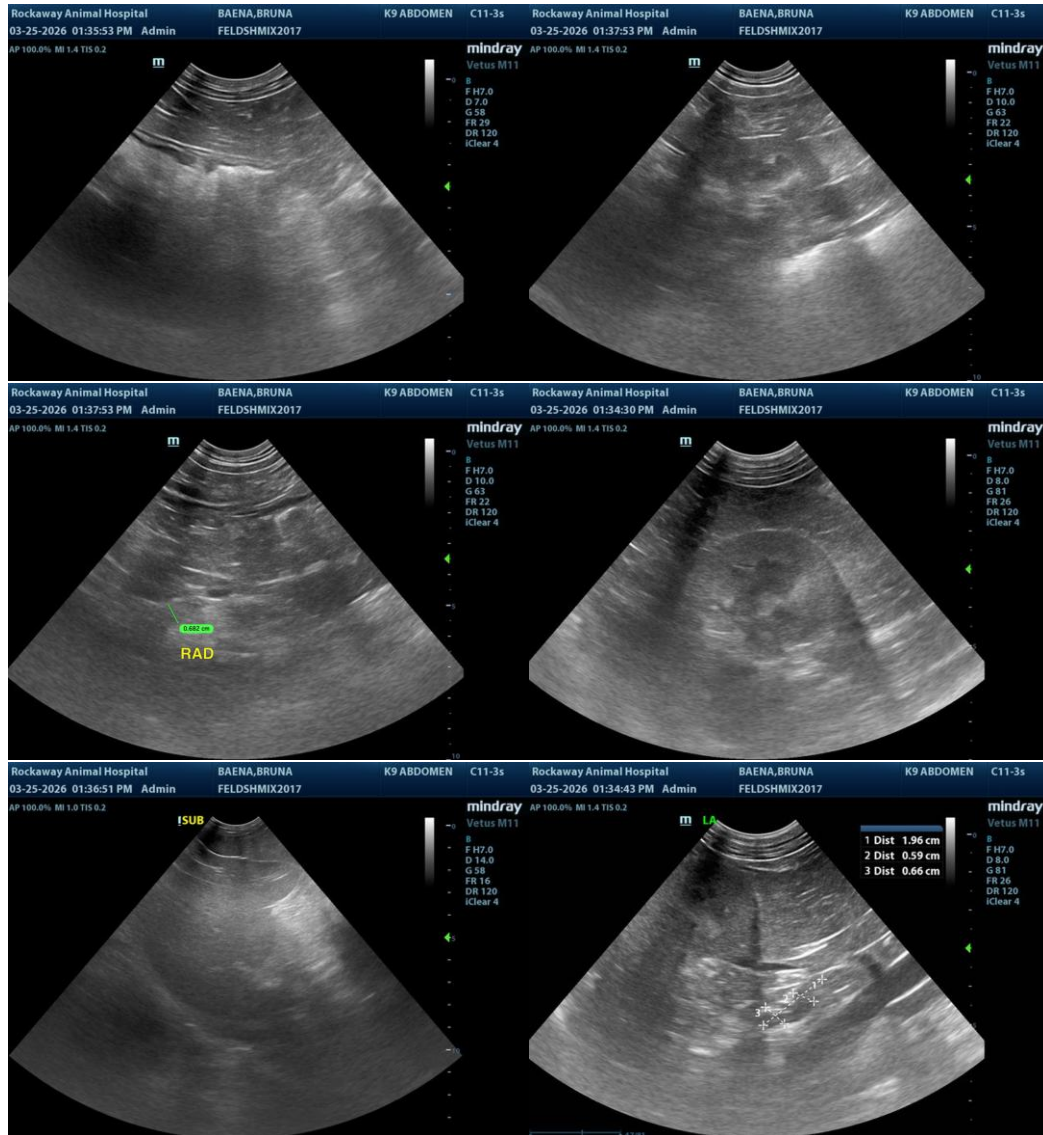
Dr Maniar

**INVOICE**

24287

**DATE**

03/25/2026





## PATIENT

Bruna Baena

## SPECIES

Canine

## BREED

Mix

## SEX

FS

## AGE

9

## WEIGHT

43.2

## INTERPRETED BY

R. McKenzie Daniel,  
DVM, DABVP  
(Canine and Feline)

## IMAGING PERFORMED BY

Jenn

## HOSPITAL NAME

Rockaway Animal  
Hospital

## REFERRING VET

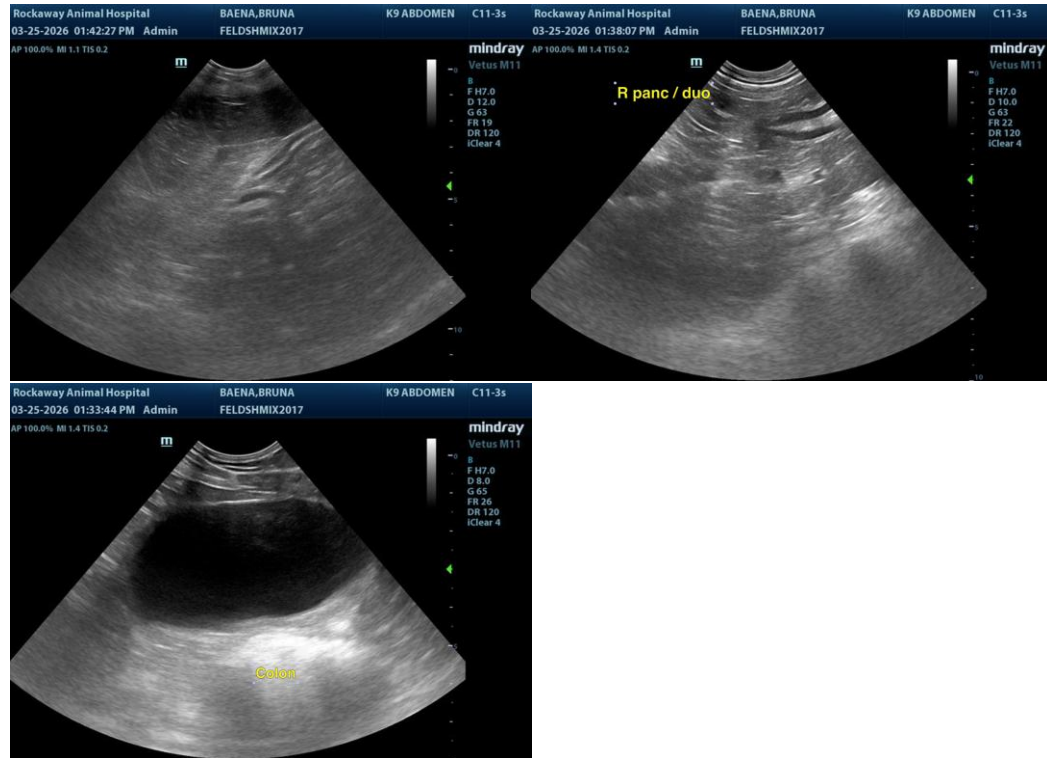
Dr Maniar

## INVOICE

24287

## DATE

03/25/2026



The information and recommendations provided are based on the images presented by the referring veterinarian/sonographer. No evaluation can be communicated regarding pathology that was not visible in the image/video clips provided.

Thank you for this referral. If the clinical or image interpretation does not parallel your findings or if I can be of any further assistance, please contact me.

R. McKenzie Daniel, DVM, DABVP (Canine/Feline Practice)  
[info@sonopath.com](mailto:info@sonopath.com)